

# Modulatory Effect of *Adhatoda vasica* Leaf Extract against $\gamma$ -Irradiation in Pectoralis Muscle of Mice

Sushma Sharma<sup>1</sup>, Mahender Singh<sup>2</sup>

Department of Biosciences, H.P. University, Summer Hill, Shimla-171005; India

**Abstract:** *Adhatoda vasica*, a popular Indian medicinal plant, has long been used commonly in Ayurvedic system of medicine. The plant has been found to possess diverse number of pharmacological activities. Oral administration of *Adhatoda vasica* (*A. vasica*) extract (900 mg/kg body weight) prior to irradiation showed a significant protection. Mice exposed to radiation (4Gy) without *A. vasica* extract pre-treatment exhibited sign of radiation sickness like anorexia, lethargicity and ruffled hairs. Mice were divided into four groups i.e. (i) control group (ii) mice given 900 mg/kg body weight of *A. vasica* extract orally (iii) mice exposed to gamma radiation (4Gy) and (iv) *A. vasica* extract treated plus irradiated group. Histopathological changes in mice pectoralis muscle has been investigated under normal, extract treated, irradiated, plant extract plus irradiated groups. There was significantly lesser degree of damage to extract treated plus irradiated muscle. But there was higher degree of damage to irradiated muscle architecture. A significant decrease in superoxide dismutase (SOD) content and increase in lipid peroxidation (LPO) level was observed in irradiated animals. However, *A. vasica* extract pretreated irradiated animals exhibited a significant increase in SOD content and decrease in LPO level.

**Keywords:** *Adhatoda vasica*, gamma radiation, pectoralis and oral administration

## 1. Introduction

Today, the large number of drugs in use are derived from plants. Several biological effects of plants and plant extracts were investigated in recent clinical and pharmacological studies. Many more medicinally useful plants are present in Himalayas. Among them is *Adhatoda vasica* that belongs to family Acanthaceae. Leaves of plant are the main source of drug preparation. It has also been accredited to afford protection against allergen induced bronchial obstruction in guinea pigs [1]. It has growth inhibitory effects on *Mycobacterium tuberculosis* thereby proving useful in the therapy of tuberculosis [2]. The drug is employed in different forms such as fresh juice, infusion and powder. The powder is reported to be used as poultice as rheumatic joints as counterirritant on inflammatory swelling, on fresh wounds, urticaria [3]. The various chemicals that have been used as radioprotectors as free radical scavengers and are effective if given prior to or during irradiation. Their toxic effects severely limit their clinical use [4].

Plants and their products are well known to have an advantage over the synthetic compounds in term of their potential low/no toxicity at the effective dose with minimum or no side effects [5]-[9]. Pectoralis muscle tissue provides an example of highly organized cytocontractile tissue exhibiting various metabolic and physiological division of labour amongst its constituent cells [10], [11]. Muscle's intact nerve supply determines the phenotypic expression of muscles and early postnatal period, is a critical stage in fiber type differentiation [12]

## 2. Materials and Methods

Swiss albino mice of Balb-C strain weighing 20-24g were procured from Central Research Institute (CRI) Kasauli, Himachal Pradesh, India. These were maintained in the animal house of department of Biosciences of Himachal Pradesh University, Shimla under proper hygienic conditions ( $24 \pm 2^{\circ}\text{C}$  temp. and light). Mice were provided Hindustan lever feed and water *ad libitum*.

The experimental animals were divided into four groups. Control group was served as normal. Second group received *Adhatoda vasica* extract orally (900 mg/kg body weight). Third group was exposed to gamma radiation (4Gy). Fourth group was *Adhatoda vasica* extract treated plus irradiated.

### Preparation of *Adhatoda vasica* extract

Leaves of *Adhatoda vasica* were collected from the herbal garden Joginder Nagar, Himachal Pradesh and were identified by taxonomist. Collected leaves were washed thoroughly and dried under shade for one month. Dried leaves were grinded to a coarse green coloured powder.

### Extraction

Dried leaves powder was extracted five times with 80% ethanol solution. Extraction was done after every twenty four hours. Collected suspension was concentrated under reduced pressure.

### Source of Irradiation

Mice were irradiated in "Gamma chamber-900" (BARC) with automatic timer having Cobalt-60 as the source of  $\gamma$ -rays. *Adhatoda vasica* extract administered daily for 28 days. After 7 days of extract administration, mice were irradiated with 4 Gy gamma radiation.

Body weight of mice of all groups was recorded on 7, 14, 21 and 28 days post treatment. Animals were killed by cervical dislocation as approved by institutional Animal Ethics Committee (IAEC/Bio/12-2009). The pectoralis muscle from both pectoralis girdles were excised and used for histological studies using Haematoxylin-eosin staining technique. The histological studies were intended to understand histopathological alternations induced by gamma irradiation and *Adhatoda* extract. At least 8 animals were sacrificed at each stage. Sections of 7-8  $\mu$  thickness were used and slides mounted in DPX were stored permanently.

### 3. Results and Discussion

The results obtained for histopathological and biochemical studies on pectoralis muscle of mice were presented in figures 1-10 and tables 1-2 and discussed as follows:

#### Normal Muscle

The transverse section of normal muscle exhibited round, oval and polygonal constituent fibers, tightly packed without any noticeable interfibrillar or interfascicular spaces (Fig. 1). Nuclei were present at sub-sarcolemmal position. Occasional interfibrillar nuclei were also visible. The intrafibrillar nuclei were randomly distributed among the muscle fibers.

#### *Adhatoda vasica* extract treated muscle

Slight changes in the pectoralis muscle architecture were noticed after oral administration of *Adhatoda vasica* extract. Normal polygonal or oval outline of the muscle tissue was slightly lost and merging of fibers were also seen (Fig. 2.). The nuclei were subsarcolemmal in position. The size of orally treated muscle fibers increases. This is in accordance with similar observation in developing human skeletal muscle [13], [14]. In certain fibers, the nuclei shifted their position deep inside the fibers towards the centre. Fibers with their intact sarcolemma were seen but some of fibers start splitting and polymorphonuclear infiltration was also noticed (Fig. 3). Atrophied and hypertrophied fibers were shown in the muscle sections and muscle fibers were variously shaped.

#### Irradiated muscle

The irradiated muscle demonstrated drastic changes in the muscle architecture. The muscle sections exhibited severely damaged muscle fibers, certain hypertrophied fibers and large interfascicular spaces (Fig. 4). The effect of gamma rays were massive, they affected cells in clusters. The present study had demonstrated that gamma radiation induced cell death in the developing muscle showed morphological features of apoptosis [15]. Nuclei were displaced from their normal sarcolemmal disposition to the interfibrillar spaces thereby increasing the interfibrillar nuclei number.

The breakdown of muscle fibers and degenerative connective tissue at 14 days stage were also observed (Fig. 5). Some of fibers undergo necrosis and merged fibers showed changes in their structure (Fig. 6) at 21 days of investigation. Radiation induced damage to normal tissues

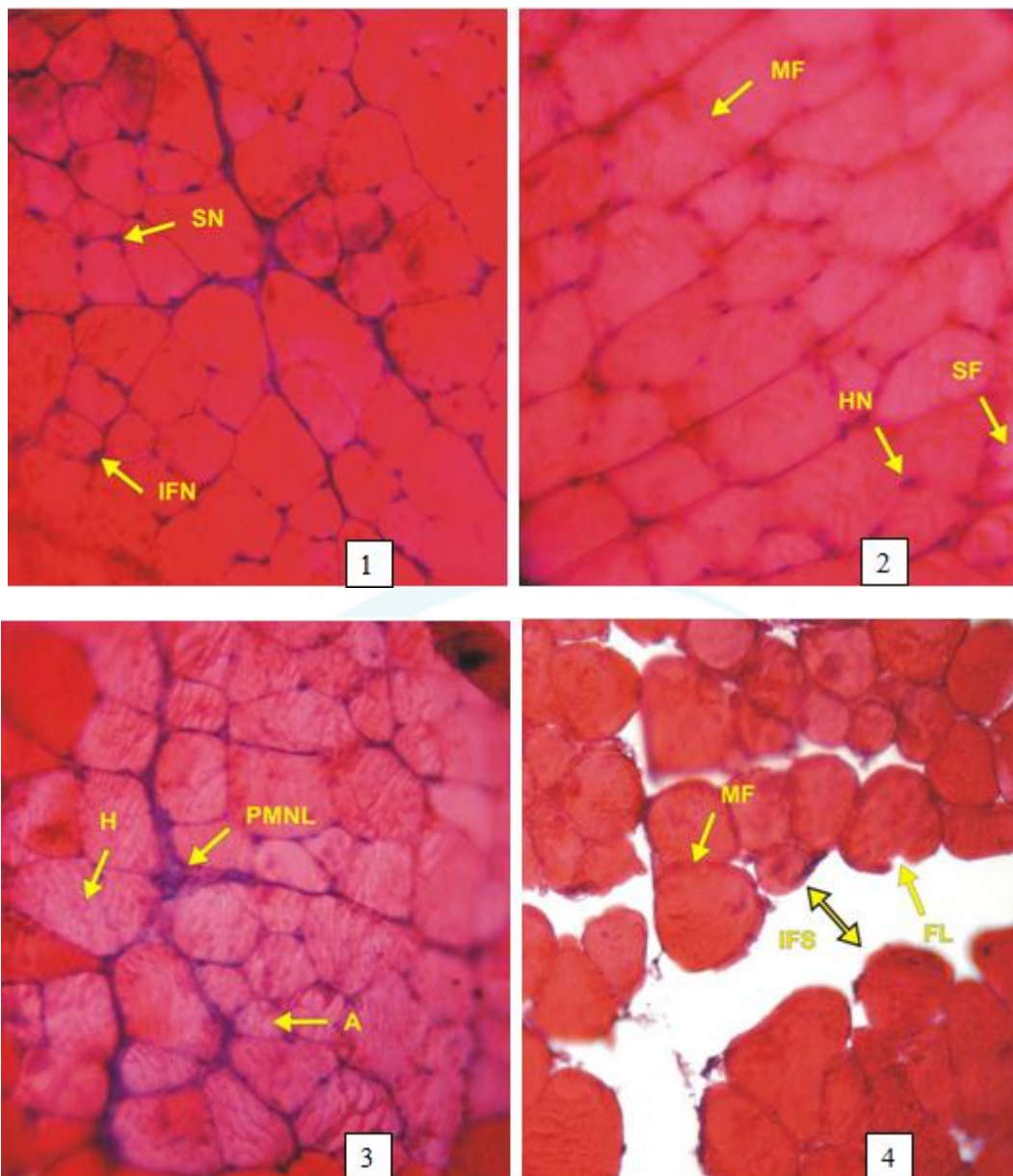
can be partially reduced by the use of radioprotectors that reduce the damaging effects of radiation [16]-[18].

#### *Adhatoda vasica* extract plus irradiated muscle

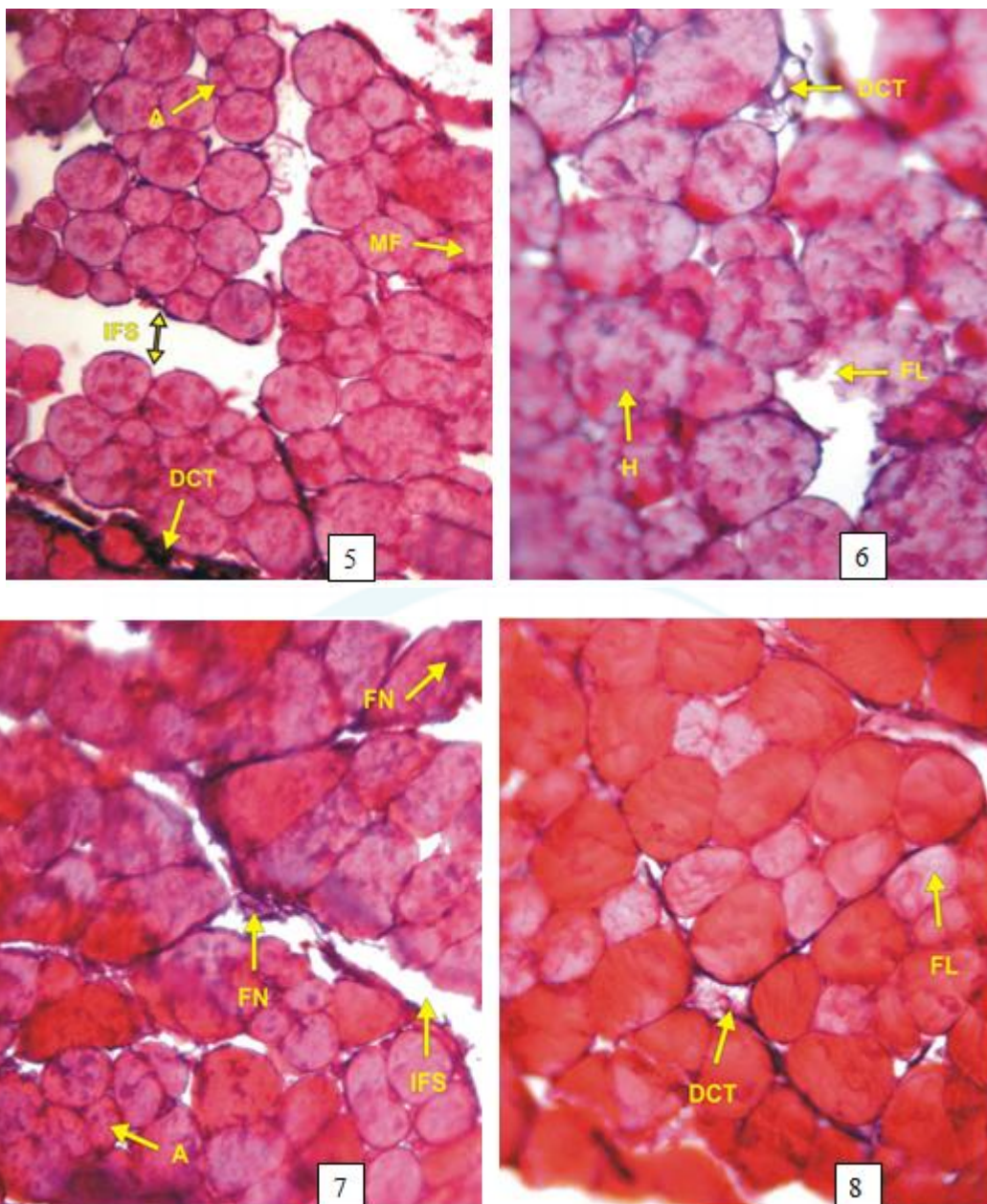
Histological examination of *A. vasica* extract pretreated plus irradiated muscle exhibited recovery in muscle fibers. *A. vasica* extract plus irradiated muscle at 28 days (Fig. 7) showed degenerative connective tissue and fibers splitting at 14 days stage (Fig. 8). Since the effects of gamma rays are suppressed when *Adhatoda* extract administered orally before irradiation, it can be suggested that gamma rays induced cell death is an active process associated with protein. A similar reduction in number of radiation induced dead cells is observed in developing skeletal muscle following *Adhatoda* extract before irradiation [19], [20]. The inter and intrafibrillar spaces were increasing and cells showing atrophy and merging of fibers after 21 days of investigation (Fig. 9). Nuclear streaks alongwith fibrolysis were seen after 28 days of investigation (Fig. 10).

Biochemical estimation of superoxide dismutase (SOD) and lipid peroxidation (LPO) levels of pectoralis muscle were presented (Table-1, 2). Superoxide dismutase levels did not show significant variation in *Adhatoda vasica* extract treated animals muscle. A significant reduction in SOD activity was observed in irradiated animals. This could be due to the enhanced utilization of antioxidant system as an attempt to detoxify the free radicals generated by radiation. The increase in SOD activity was observed in *Adhatoda* extract pretreated and irradiated animals. An extract of *Phyllanthus amarus* has been reported to protect against radiation induced decline in SOD and reduced glutathione (GSH) [21]. Thus, studies showed that various plant and herbs protect against radiation induced damage by scavenging free radicals and increasing antioxidant level.

It is observed that although, *Adhatoda vasica* leaf extract treatment did not significantly alter lipid peroxidation (LPO) level in normal animals. But, *A. vasica* leaf extract pretreatment significantly lower the radiation induced LPO levels in terms of malondialdehyde. Inhibition of LPO in biomembranes can be caused by antioxidant [22], [23]. It has been shown that more  $\alpha$ -tocopherol is needed in the membranes to protect poly unsaturated fatty acids against radiation induced LPO when dose of 900 mg/kg body weight is applied [24]. The results from the present investigation indicated that *A. vasica* leaf extract pretreatment protected against radiation damage by inhibiting radiation induced SOD depletion and decreasing LPO levels in mice.



- Fig. 1: T.S. of normal mice pectoralis muscle at 21 days stage showing round, oval and polygonal constituent fibers without any noticeable interfibrillar or intrafascicular spaces. Interfibrillar nuclei (IFN) and sub-sarcolemmal disposition of nuclei (SN) is also witnessed X400.
- Fig. 2: T.S. of *Adhatoda vasica* extract treated mice pectoralis muscle at 7 days stage exhibiting merged fibers (MF), split fibers (SF) and hypertrophied nuclei (HN) X400.
- Fig. 3: T.S. of *Adhatoda vasica* extract treated mice pectoralis muscle at 21 days stage exhibiting polymorphonuclear infiltration ((PMNL) and hypertrophied (H) and atrophied (A) X400.
- Fig. 4: T.S. of pectoralis muscle of irradiated mice at 7 days stage showing merging of fibers (MF) and fibrolysis (FL). Large inter fascicular spaces are observed (↓) X400.



- Fig. 5: T.S. of irradiated mice pectoralis muscle at 14 days stage demonstrating merging of fibers (MF) and atrophied (A). Degenerative changes of connective tissues (DCT) are also seen X400.
- Fig. 6: T.S. of irradiated mice pectoralis muscle at 21 days stage exhibiting atrophied (A) and hypertrophied (H) muscle fibers. Degenerating connective tissue (DCT) and fibrolysis (FL) is also seen X400.
- Fig. 7: T.S. of irradiated mice pectoralis muscle at 28 days stage demonstrating fiber necrosis (FN) and interfascicular spaces (IFS) X400.
- Fig. 8: T.S. of *Adhatoda vasica* extract and irradiated mice pectoralis muscle at 14 days stage depicting round cells with fibrolysis (FL) and degenerating connective tissue (DCT) X400.

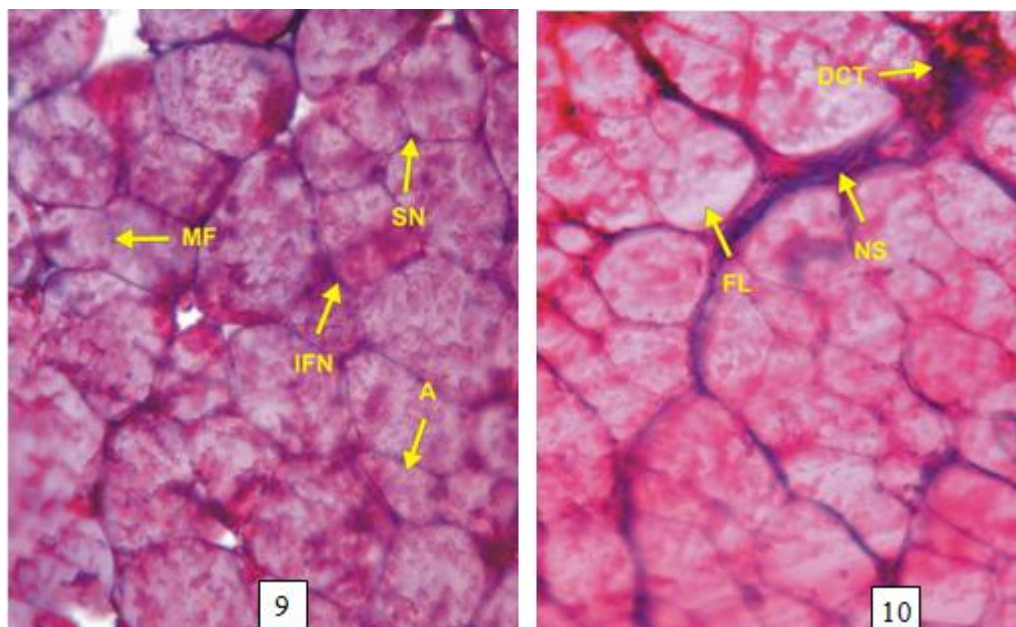


Fig. 9: T.S. of *Adhatoda vasica* extract and irradiated mice pectoralis muscle at 21 days stage showing fiber atrophy (A), merging of fibers (MF) and inter fibrillar nuclei (IFN) X400.

Fig. 10: T.S. of *Adhatoda vasica* extract and irradiated mice pectoralis muscle at 28 days stage showing lysis of fibers (FL), degenerating connective tissues (DCT) and streaks of nuclei (NS) X400.

**Table 1:** Change in superoxide dismutase specific activity (units/mg protein) in pectoralis muscle of Swiss albino mice in different groups

Values are mean  $\pm$  SEM; n = 3 ( $p < 0.05$ )

Groups	Days			
	7	14	21	28
N	10.62 $\pm$ 0.99	10.75 $\pm$ 1.91	10.89 $\pm$ 2.49	10.93 $\pm$ 1.55
AE	11.18 $\pm$ 1.02*	11.87 $\pm$ 1.36*	12.00 $\pm$ 1.78*	12.15 $\pm$ 1.51*
IR	7.01 $\pm$ 2.60	7.95 $\pm$ 1.48	8.50 $\pm$ 2.58	8.92 $\pm$ 0.85
AE+IR	8.23 $\pm$ 0.05*	8.81 $\pm$ 1.28*	9.02 $\pm$ 1.72*	9.96 $\pm$ 0.83

N = Normal; AE = Adhatoda extract treated; IR = Irradiated; AE+IR = Extract treated + irradiated

**Table 2:** Change in lipid peroxidation activity (n moles of TBARS formed/g of fresh tissue weight) in pectoralis muscle of Swiss albino mice in different groups

Values are mean  $\pm$  SEM; n = 3 ( $p < 0.05$ )

Groups	Days			
	7	14	21	28
N	4.47 $\pm$ 0.21	4.39 $\pm$ 0.15	4.83 $\pm$ 0.27	4.99 $\pm$ 0.15
AE	4.72 $\pm$ 0.06	4.51 $\pm$ 0.22*	4.98 $\pm$ 0.46*	5.19 $\pm$ 0.12*
IR	12.94 $\pm$ 0.83	13.09 $\pm$ 2.19	14.62 $\pm$ 0.99	14.94 $\pm$ 0.99
AE+IR	9.75 $\pm$ 0.81	9.87 $\pm$ 1.36	9.98 $\pm$ 0.96	10.22 $\pm$ 1.51

N = Normal; AE = Adhatoda extract treated; IR = Irradiated; AE+IR = Extract treated + irradiated

## References

- [1] Dorsch W and Wagner H, New antiasthmatic drugs from traditional medicine? *Int. Arch. Allergy Appl Immunol*, 94, (1991) 262-265.
- [2] Grange J M and Snell N J, Activity of bromhexine and ambroxol, semisynthetic derivatives of vasicine from the Indian Shrub *Adhatoda vasica*, against mycobacterium tuberculosis in vitro, *J Ethnopharmacol*, 50, (1996) 49-53.
- [3] Claeson U P, Malmfors T, Wikman G, Bruhn J G, *Adhatoda vasica*: a critical review of ethnopharmacological and toxicological data, *J Ethnopharmacol*, 85, (2003) 261-267.
- [4] Bacq Zm, International encyclopedia of pharmacology and therapeutic, (1975) 319-323.
- [5] Ammon H P and Wahl M A, Pharmacology of Curcuma longa, *Planta Medica*, 57 (1991) 1-7.
- [6] Scarterzzimi P and Speroni E, Review of some plants of Indian traditional medicine with antioxidant activity, *J Ethnopharmacol*, 71, (2000) 23-43.
- [7] Weiss J F and Landaver M R, Protection against ionizing radiation by antioxidant nutrients and phytochemicals, *Toxicol*, 189, (2003) 1-20.
- [8] Coleman C N, Stone H B, Moulder J E and Pellmar T C, Modulation of radian injury, *Science* 304, (2004) 693-694.
- [9] Sarkar F H and Li Y, The role of isoflavones in cancer Chemo-prevention, *Frontiers in Bioscience*, 9, (2004) 2714-2724.
- [10] Sher J and Cardasis C, Skeletal muscle fiber types in the adult mouse, *Acta Neurol Scandinav*, 54, (1976) 45.
- [11] Katoch S S and Malhotra R K, Nuclear behaviour in denervated chick skeletal muscle, *Pavo*, 20, (1982) 22.
- [12] Redenbach D M, Ovalle W K, and Bressler B H, Effect of neonatal denervation on the distribution of fiber types in a mouse fast-twitch skeletal muscle, *Histochemistry*, 4, (1988) 333.
- [13] Webb J N, The development of human skeletal muscle with particular reference to muscle cell death, *J Pathol*, 106, (1972) 221-228.
- [14] Webb J N, Cell death in developing skeletal muscle: histochemistry and ultrastructure, *J Pathol*, 123, (1977) 75-180.
- [15] Fidzianska A and Goebel H H, Human ontogenesis. Cell death in fetal muscle, *Acta Neuropathologica*, 81, (1991) 572-577.
- [16] Kumar A, Ram J, Samarth R M and Umar M K, Modulatory influence of *Adhatoda vasica* Nees leaf

- extract against gamma irradiation in Swiss albino mice, *Phytomedicine*, 12, (2003) 285-293.
- [17] Stone H B, Moulder J E and Coleman C N, Models for evaluating agents intended for the prophylaxis, mitigation and treatment of radiation injuries, *Rad Res*, 162, (2003) 711-728.
- [18] Baliga M S, Jagetia G C, Venkatesh P and Ullor J N, Radio protective effect of abana, a polyhedral drug following total body irradiation, *British J Radiol*, 77, (2004) 1027-1035.
- [19] Ferrer I, The effect of cycloheximide on natural and x-ray induced cell death in developing cerebral cortex, *Brain Research*, 588, (1992) 351-357.
- [20] Ferrer I, Serrano T, Rivera R, Olive M, Zujar M J and Graus F, Radiosensitive populations and x-ray induced apoptosis in developing cerebellum, *Acta Neuropathologica*, 86, (1993) 491-500.
- [21] Kumar K B and Kuttan R, Protective effect of an extract of *Phyllanthus amarus* against radiation induced damage in mice, *J Rad Res (Tokyo)*, 45, (2004) 133.
- [22] Konings A W T and Drijver E B, Radiation effects on membranes. I. vitamin E deficiency and lipid peroxidation, *Radiat Res*, 80, (1979) 494-501.
- [23] Konings A W T and Osterloo S K, Radiation effects on membranes. II. A comparison of the effects of x-irradiation and ozone exposure with respect to the relation of antioxidant concentration and the capacity for lipid peroxidation, *Rad Res*, 81, (1980) 200-207.
- [24] Konings A W T, Damen J and Trieling W B, Protection of liposomal lipids against radiation induced oxidative damage, *Int J Rad Biol*, 35, (1979) 343-350.

IJSER