

Mucinous Carcinoma of Breast: Cytodiagnosis of 2 Cases

Sujata S Giriyan¹, Rajesh H Chandan², Lata D Annigeri³

¹Professor and Head, Department of Pathology, Karnataka Institute of Medical Sciences, Hubballi

²Associate Professor, Department of Pathology, Karnataka Institute of Medical Sciences, Hubballi

³Post Graduate Student, Department of Pathology, Karnataka Institute of Medical Sciences, Hubballi

Abstract: *Pure Mucinous carcinoma of the breast is relatively rare, accounting for 2% of all breast cancers. Commonly presenting in postmenopausal age group. Here we report 2 cases, postmenopausal age group female patients, presented with lump in the unilateral breast. On fine needle aspiration cytology, diagnosis of mucinous or colloid carcinoma of the breast with no lymph node metastasis was made and subsequently confirmed by Histopathology. Knowledge of the distinctive cytomorphological appearance of Mucinous carcinoma would enable correct identification of these lesions as malignant and prompt treatment that could further enhance the survival of these prognostically good breast cancers.*

Keywords: Breast, Fine needle aspiration cytology, Colloid carcinoma

1. Introduction

Mucin-producing carcinomas of the breast have been described in pure form and as mixed mucinous-ductal type^[1]. Pure Mucinous carcinoma of the breast is relatively rare, accounting for 2% of all breast cancers, usually seen in postmenopausal age group having better prognosis than the mixed variety. This tumor shows characteristic features of mucin production by the tumor^[2] and in general mucinous component is 50% or more^[3, 4]. In the mixed type tumor, the mucinous component is admixed with infiltrating epithelial component.

Fine needle aspiration (FNA) yields copious amounts of mucinous material with variable proportion of tumor cells which are being generally small and fairly uniform with minimal atypia that gives false impression of benignancy. The mucinous carcinoma should be distinguished from other breast lesions such as mucocele like lesions, mucinous cyst and mucinous spherulosis^[5]. The present report describes the spectrum of distinct cytological features.

2. Case Report

CASE 1- 52yr female patient presented with painful large lump in lower outer quadrant in right breast since two months.

CASE 2- 50yr female patient presented with painful large lump in central quadrant of right breast since one month.

In both of the cases, lump was fixed to the underlying structures. The overlying skin and nipple areola complex were normal with no lymph node involvement. Clinically diagnosed as carcinoma of breast and FNAC was advised in both cases.

Fine needle aspiration was performed using 23 gauge needle attached to a 10 ml syringe and aspirated gelatinous material were deposited onto clean glass slide and smeared. Air dried smears were fixed in 100%

methanol for Giemsa stain. Smears for Papanicolaou stain and H & E stains were wet fixed in 100% isopropyl alcohol.

3. Pathological Findings

On Fine needle aspiration:

Case 1: Smears showed abundant pink mucoid material with numerous moderately pleomorphic epithelial cells lying either discretely forming loose clusters or entrapped within stromal material along with blood vessels having chicken wire appearance.

Case 2: In addition to the above features it had round to oval cells with eccentric, round to oval vesicular nuclei (plasmacytoid appearance) and moderate amount of basophilic cytoplasm and cytoplasmic vacuole. Few cells with intracytoplasmic mucin appearing as signet ring cells were distributed predominantly in singles.

In both cases the cytological features were suggestive of Mucin secreting carcinoma.

Modified radical mastectomy was done in both the cases. Histological specimens were fixed in formalin and processed routinely for Hematoxylin and Eosin (HE) stain.

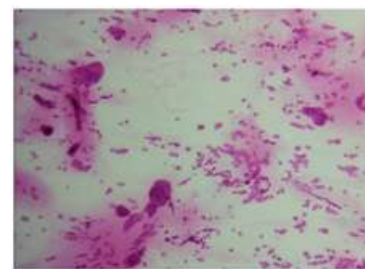


Figure 1: H&E (4X) Smear from mucinous carcinoma showing scanty mucin, high cellularity

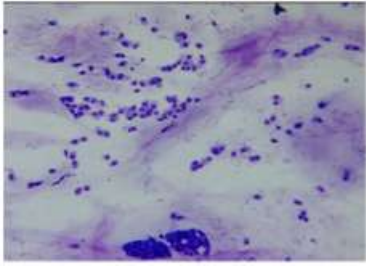


Figure 2: wrights (4X) Sheets of bland tumour cells with mild nuclear pleomorphism in a sea of mucin

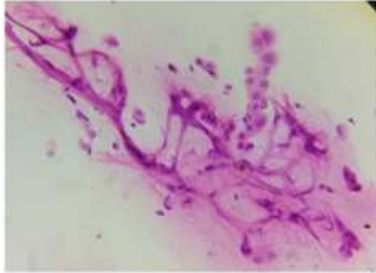


Figure 3: H&E (10X) Microvascular branches giving chicken wire appearance

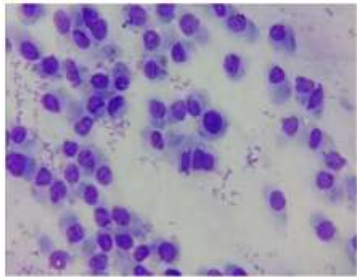


Figure 4: Wrights (40X) Signet-ring cells in smear from mucinous carcinoma

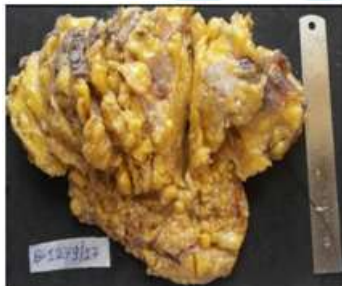


Figure 5: Modified radical mastectomy specimen 5cmX4cmX2.5cm.

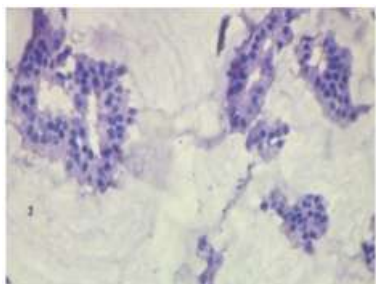


Figure 6: H&E(10X)Sheets of bland tumour cells surrounded by mucin giving a whirlpool effect

4. Histopathological Findings

Gross features:

On Cut section grey brown, solid to cystic poorly circumscribed tumor, in first case specimen measured 5cmX4cmX2.5cm and in second case measured 5cmX3cmX2.5cm in greatest dimension with variegated appearance seen and cystic space filled with gelatinous material. Lymph nodes were unremarkable.

Microscopic features: Sheets of bland tumour cells surrounded by mucin giving a whirlpool effect. Mucinous carcinoma of breast was confirmed on histopathology.

5. Discussion

Pure mucinous carcinoma is a rare histologic type of mammary neoplasm, seen in elderly women and has a better prognosis than usual invasive ductal carcinoma^[6, 7, 8]. FNA cytology reporting of malignant breast lesions does not usually include the categorization of tumour type. To the inexperienced eye, the relatively bland features of the tumour cells from Mucinous carcinoma may suggest a benign lesion. However, even while looking through the 4x or 10x objective, the "sea of mucin" or "whirlpool" effect of the extracellular mucin bathing these bland cells and usually jelly like mucin aspirate is a very distinctive clue to the identification of MC^[8]. This feature was seen in both cases in the present study.

However, the presence of only mucin does not warrant a diagnosis of MC as other breast lesions i.e. mucocele like lesions, mucinous cyst and mucinous spherulosis also show extracellular mucin^[5].

Signet-ring cells being rare or absent in pure Mucinous Carcinoma of the breast but may be seen in mixed MC and Invasive ductal carcinoma (IDC) of the usual type. The signet-ring cell variant of Inter lobular carcinoma (ILC) rarely has an extracellular component and must be distinguished from pure Mucinous Carcinoma and other carcinomas owing to their vastly differing prognosis^[9].

6. Conclusion

Knowledge of the distinctive cytomorphological appearance of Mucinous carcinoma and their variety would enable correct identification of these lesions as malignant and prompt treatment that could further enhance the survival of these prognostically good breast cancers^[10].

References

- [1] S. Sharma, R. Bansal, A. Khare, et al., Mucinous carcinoma of breast: Cytodiagnosis of a case, J cytol. 2011 Jan-Mar; 28(1): 42-44.
- [2] Tellem M, Nedwich A, Amenta PS, Imbriglia JE. Mucin-producing carcinoma of the breast. Tissue culture, histochemical and electron microscopic study. Cancer 1966;19:573-84.

- [3] Nagoo KS, Rohaizak M, Naqiyah I, Shahrun Niza AS. Male breast cancer: experience from a Malaysian tertiary centre. Singapore Med J 2009; 50: 519-21.
- [4] Fentiman IS, Fourquet A, Hotobagyi GN. Male breast cancer. Lancet 2006; 367: 595-604.
- [5] Fine needle aspiration cytology findings of mucinous carcinoma of breast: a study of eight cases with histological correlation. Journal of pathology of Nepal(2012) vol 2: 285-288
- [6] Peng L, Sun Q, Liang ZY, Zhou YD, Mao F, Guan JH. Pure mucinous carcinoma of the breast: a clinicopathologic analysis with 56 patients. Chin Med Sci J 2010;25:115-8
- [7] Komaki K, Sakamoto GA, Sugano H, Morimoto T, Monden Y. Mucinous carcinoma of the breast in Japan: a prognostic analysis based on morphological features. Cancer 1988;61: 989-96
- [8] Diab SG, Clark GM, Osborne CK, Libby A, Allred DC, Elledge RM. Tumor characteristics and clinical outcome of tubular and mucinous breast carcinomas. J Clin Oncol 1997;17:1442-8
- [9] G. Jayaram, M.Swain, MT Chew, et al. Cytology of mucinous carcinoma of breast: a report of 28 cases with histological correlation, Malasian J pathol. 2000; 22(2) : 65 – 71
- [10] J. Cyrta, F. Andreiuolo, S. Azoulay, et al., Pure and mixed mucinous carcinoma of the breast: fine needle aspiration cytology findings and review of the literature. Cytopathology. 2013 24(6):377-384
- [11] Orell SR, sterret GF, fine needle aspiration cytology, 5th edition Edinburgh Churchill Livingstone, 2012, 190-192
- [12] Di Saverio S, Gutierrez J, Avisar E. A retrospective review with long term follow up of 11, 400 cases of pure mucinous carcinoma. Breast Cancer Res Treat 2008;111:541-7
- [13] Andre S, Cunha F, Bernardo M, Meneses e Sousa J, Cortez F, Soares J. Mucinous carcinoma of the breast: a pathologic study of 82 cases. J Surg Oncol 1995;58:162-7