

Overlapping of CK7 and HOXB4 with Some Histopathological Variables in Ovarian Cancer Patients

Nuha Alaa Hamza, Kareem Hamed Ghali, Hameed Naeem Mousa¹

Department of Biology, College of Science, University of Wasit, Iraq

¹Department of Pathology and Forensic Medicine, College of Medicine, Thi Qar University, Iraq

Abstract: Ovarian carcinoma (OC) is one of the most common cancers ranks 7th in both incidence and mortality among women worldwide. The study included fifty three samples of ovarian tumor patients, twenty eight of them were malignancy and twenty five were benign. Those patients' samples then compared with twenty three of non-cancer tissues samples as control group. This study was carried out in Laboratories of the College of Science / Department of Biology, Wasit University, during period between 1 November 2017 to 1 November 2018. The study of CK7 and HOXB4 genes expression was done by immunohistochemistry (IHC) technique. The results showed significant correlation between CK7 and HOXB4 in OC. Overlapping effects of histopathological variables in ovarian cancer patients with CK7 expression, showed no significant ($p > 0.05$) correlation coefficient between OC and histopathological variables (stage, grade and type) in related to CK7 expression. HOXB4 showed significant ($p < 0.05$) correlation with age and stage and no significant with other histopathological variables (grade and type). From the results presented, it was concluded that the present study reveals that both CK7 and HOXB4 expression may play necessary roles in carcinogenesis and development of ovarian cancer. This study suggests to use CK7 and HOXB4 proteins as additional biomarkers in diagnosis, follow up and treatment of ovarian cancer.

Keywords: Cancer, Ovarian, CK7, HOXB4, Correlation, Overlapping

1. Introduction

Ovarian cancer is the most fatal gynaecological cancer, with more than 150 000 women succumbing to the disease each year worldwide [1]. The 5-year survival rate is less than 50% [2]. Reasons for this high mortality rate include diagnosis at advanced stages and acquired resistance to chemotherapeutic drugs such as cis-platin and carboplatin [3]. The median age of patients enrolled in most randomised trials is 58 years. Women with a genetic predisposition to ovarian cancer are diagnosed roughly 10 years earlier than the median age of diagnosis [4]. Women are frequently diagnosed with advanced stage disease because of the vague nature of the presenting symptoms [5]. Nearly all benign and malignant ovarian tumors originate from one of three cell types: epithelial cells, stromal cells, and germ cells. In developed countries, more than 90% of malignant ovarian tumors are epithelial in origin, 5%–6% of tumors constitute sex cord-stromal tumors (e.g., granulosa cell tumors, thecomas, etc.), and 2%–3% are germ cell tumors (e.g., teratomas, dysgerminomas, etc.) [6].

Cytokeratins (CKs), a set of polypeptides of different molecular weights, comprise the main type of intermediate filaments in epithelial cells and provide scaffold structures within cells [7]. The specific nature of these heterodimers serves to distinguish different epithelial cells, in which they are expressed, and has also become important in the classification of tumor cells besides other protein tumor markers. Mutations in most of them are now associated with specific tissue-fragility disorders, and antibodies to cytokeratin are important markers of tissue differentiation [8]. Cytokeratin 7 (CK7) can be used as a tool in order to distinguish ovarian and gastrointestinal carcinomas, or transitional cell carcinomas and prostate cancer. In

hepatocytes atypical expression is a marker for primary biliary cirrhosis [9].

HOXB4 is one of four HOX group 4 paralogs of the antenapedia (ANTP) homeobox superfamily genes. It is located on chromosome 17 and encodes a nuclear protein that functions as a transcriptional factor implicated in cellular differentiation and development [10]. In humans, HOXB4 has been studied extensively in the hematopoietic stem (HS) and progenitor cells in vivo and in vitro [11]. HOXB4 over expression in HS cells enhance the differentiation and expansion of these embryonic stem cells, yet this effect is lost in the adult cells. One of the functions of HOX genes in cancer is to regulate cancer cell migration and invasion [12]. Aberrant expression of HOX genes in epithelial ovarian cancer (EOC) is thought to be a contributor in ovarian tumor progression [13]. HOXB4 has invasion-suppressive effects on ovarian cancer cells, and this effect is partially mediated by CD44 [14]. This study was designed to investigate the correlation between both genes expression, CK7 and HOXB4, as well as to find the overlapping between above genes and some pathological variables in ovarian cancer such as age group, stage, grade and histological type.

2. Materials and Methods

2.1 Patients group study

Twenty eight tissue samples were collected from ovarian tumor patients, which were diagnosed as OC patients by physicians and specialist's pathologists, their age ranged between 19 and 81 years. All samples of patients were collected from Al- Karama and AL- Zahraa Teaching Hospitals in Wasit Province, and from Private Laboratory (Ibn Al-Bitar) in Thi Qar Province. Clinical information were

obtained involving, clinical examination, and histopathological parameter include type, age, stage and grade. All tissue samples were embedded in paraffin.

2.2 Immunohistochemistry (IHC)

CK7 and HOXB4 antibodies and ABC staining system were used provided by Abcam Biotechnology. Serial tissue sections were cut at 4-5µm thick and positioned on positive charged slides. The slides were packed at 60-65°C oven overnight. The tissue sections were deparaffinized; then the slides were rehydrated by graded ethanol concentration (100%, 95%, and 70%) and xylene concentration (100%) and distal water. The slides were treated with tris EDTA for 20 minutes, and then washed twice in distal water for 2 minutes. After preparation of tissue sections, incubated in hydrogen peroxide (H2O2) diluted in D.W. for 10 minutes. Each slide was washed in PBS twice for 5 minutes. Sections were incubated for ten minutes in protein blocking serum diluted with PBS. Primary antibody was applied over night at room temperature or overnight at 4° C in humidity chamber. Slides were washed with three changes of PBS for 5 minutes each, and then slides were incubated for 60 minutes with biotinylated secondary antibody and washed with two times of PBS for 5 minutes. Sections were incubated for 10 minutes with streptavidin peroxidases, after that washed with three times of PBS for 5 minutes then the section were incubated with DAB stain for 15 min. The slides were washed in PBS, for 3 min for three time. Hematoxylin stain was added on slides for 43 seconds. Immediately, slides rinsed with running tap water for 2 minutes. Dehydrated sections as follows: 1x 95% ethanol for 20 seconds and free ethanol at 2 times for 20 seconds and xylene at 1 time for 10 seconds. Immediately 1-2 of DPX solution was added and covered with glass cover slip. Finally, slides were observed by light microscope.

Ethical consent

The study was submitted and approved by the College of Science, University of Wasit.

Statistical analysis

For all statistical analyses, the SPSS system for personal computer was used, and p values of 0.05 or less were regarded as statistically significant. Sensitivity and specificity of the tests (with 95% exact confidence intervals) were determined in studied group. Correlation between CK7 and HXB4 expression with age, grade, stage, and tumor type of ovarian cancer using correlation coefficient analyses (Person and Spearman’s rho).

Scoring system

Based on the percentage of stained cells and the intensity of nuclear stain. The staining and intensity were scored as follows: The percentage of positive staining (P) were scored as, 1 (1%-25%), 2 (26%-50%), and 3 (51%-100%), and the levels of intensity of staining (I) were determined as 0 for negative; 1 for weak staining; 2 for moderate staining; and 3 for strong staining.

3. Results and Discussion

3.1 Correlation between CK7 expression and overlapping effects of histopathological variables in ovarian cancer patients

The statistical analysis of correlation between CK7 expression with age, grade, stage, and tumor type of ovarian cancer using correlation coefficient analyses (Person and Spearman’s rho), showed no significant correlation coefficient in CK7 expression with overlapping for all variables (P≥0.05) (P≥0.05) (Table 1).

Table 1: Correlation between CK7 expression and overlapping effects of clinicopathological variables in ovarian cancer patients

Variables	Expression + -		Person factor R P	RHO factor P R
	NO%	NO%		
Age (groups)	3	2	-0.404 P≥0.05	-0.439 P≥0.05
Less than 30	60%	40%		
30-39	4	0		
40-49	6	0		
50-59	8	0		
More than 60	5	0		
Histological type	8	0	-0.328 P≥0.05	-0.322 P≥0.05
Mucinous adenocarcinoma	100%	0%		
Serous adenocarcinoma, Papillary adenocarcinoma	10	0		
Others (Dys germ cell tumors, Granulosa cell, tumors, squamous cell carcinoma, Brenner tumor, transitional cell tumors , yolk sac tumors, endometrioid adenocarcinoma	80%	20%		
Grade	10	0	-0.202 P≥0.05	-0.607 P≥0.05
G1	100%	0%		
G2	10	2		
G3	83.3%	16.7%		
Stage	15	2	-0.218 P≥0.05	-0.204 P≥0.05
S1	88.2%	11.8		
S2	8	0		
S3	3	0		
S4	0	0		
	0%	0%		

Age is an important factor in a large number of cancers and may interfere with the expression of CK7 in ovarian cancer, Result of Shin, et al., (2010) reported that age associated with CK7 expression in ovarian cancer [15]. However, our study did not detect a correlation between age and CK7 expression; this is may be due to the small sample studied. Although, our study did not showed overlapping between other variables (type, grade and stage) with CK7 expression in ovarian cancer. Other study, recordedCK7 is as negative staining express inovarianmetastases adenocarcinomas (Tot, 2002) [16]. However, Kriplani and Patel (2013) found that CK7 is a useful marker to differentiate between primary

serous tumors and primary mucinous tumors [9]. As well as, Miyamoto et al. (2018) showed all endometrial seromucinous cases had positive IHC staining for CK7, which was the similar results observed in ovarian seromucinous Vang et al. (2006) [17, 18].

3.2 Correlation between HOXB4 gene expression and overlapping effects of histopathological variables in ovarian cancer patients

The statistical analysis between HOXB4 expression with age, grade, stage, and tumor type of ovarian cancer using correlation coefficient (Person and Spearman’s rho), showed significant correlation coefficient between HOXB4 expression with age groups and tumor stage (P=0.02) (P=0.001), tumor grade and histological type of tumor were showed no significant correlation with overlapping of HOXB4 expression in ovarian cancer (P=0.6) (P=0.2), as shown in (Table 2). Although some studies revealed there are correlation between HOX family genes with histopathological variables in ovarian cancer, our study showed only age and stage were correlated with HOXB4 expression. Cheng et al. (2005) showed overexpression of HOXA9 in serous subtypes, while HOXA10 and HOXA11 over expressed in endometrioid mucinous [19]. Yamashita et al., (2006) showed both HOXB7 and B13 expression was correlated to the invasion in ovarian cancer cells [20]. Regarding stage, our study common in agreement with study of Kelly, (2014) who reported a lower level of HOX expression were correlated with stage IV in ovarian cancer [21]. Also, the result of Zhang, (2014) showed that borderline significant correlated with FIGO stage (p=0.0685), as well as, he was detected that HOXB4 associated with high-grade serous carcinoma in the fimbrial epithelium of fallopian tube [14]. Ovarian with high grade serous cell lines was showed overexpression of HOXB4 (Kelly et al. 2016) [22]

Table 2: Correlation between HOXB4 expression and overlapping effects of clinic pathological variables in ovarian cancer patients

Variables	Expression + -		Person factor R P	RHO factor P R
	NO%	NO%		
Age (groups)	4	1	-0.029 P≤0.05	-000 P≤0.05
Less than 30	80%	20%		
30-39	4	0		
	100%	0%		
40-49	6	0		
	100%	0%	-0.322 P≥0.05	-0.328 P≥0.05
50-59	8	0		
	100%	0%		
More than 60	4	0		
	80%	0%	-0.607 P≥0.05	-0.202 P≥0.05
Histological type	8	0		
Mucinous adenocarcinoma	100%	0%		
Serous adenocarcinoma, Papillary adenocarcinoma	10	0	-0.000 P≤0.05	-0.030 P≤0.05
Others (Dys germ cell tumors, Granulosa cell, tumors, squamous cell carcinoma, Brenner tumor, transitional cell tumors, yolk sac tumors, endometrioid adenocarcinoma)	8	2		
	80%	20%		
Grade	10	0	-0.000 P≤0.05	-0.030 P≤0.05
G1	100%	0%		
G2	11	1		
	91.7%	8.3%		
G3	5	1		
	83.3%	16.7%		
Stage	16	1	-0.000 P≤0.05	-0.030 P≤0.05
S1	94.1%	5.9%		
S2	7	1		
	87.5%	12.5%		
S3	3	0		
	100%	0%		
S4	0	0		
	0%	0%		

3.3 Correlation between CK7 and HOXB4 expressions in ovarian cancer patients

When we attempt to detect the correlation between those two proteins in OC, we find significant statistical correlation between those proteins (CK7 and HOXB4) in OC patients, using correlation coefficient (Qualitative Person and Quantitative Spearman’s rho), which appeared (R=-0.462) (P≤0.01), as shown in (Table 3) (Fig 1).

Table 3: Correlation between CK7 and HOXB4 expressions in ovarian cancer patients

Gene	Expression + -		Person factor P value	Spearman's factor (Rho) P value
	NO%	NO%		
CK7	26	2	-0.462	≤ 0.01
	9.92	7.1		
HOXB4	26	2	-0.462	≤ 0.01
	9.92	1.7		

Unfortunately, there have been no studies done a comprehensive study between HOXB4 and CK7 expression and some histopathological variables such as age, type, grade and stage in ovarian cancer, so, our study may considered as a key information in this field.

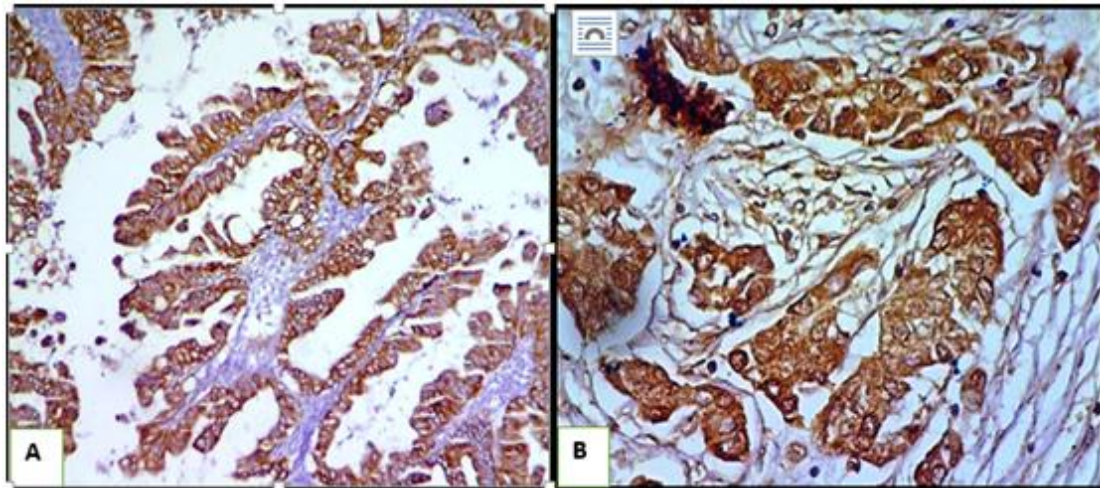


Figure 1: IHC positive staining in ovarian cancer patients (A) CK7 (B) HOXB4

3.4 CK7-HOXB4 expression in ovarian cancer and benign patients

In this test we used 25 cases of benign patients as control group, as shown in Table (4).

Table 4: CK7-HOXB4 expression in ovarian cancer and benign patients

Case	Expression + -		Total	P Value
	+	-		
Ovarian cancer CK7-HOXB4	25 89.3%	3 10.7%	28	p≤0.01
Benign patients CK7-HOXB4	11 44%	14 56%	25	
Total	36	17	53	

The result showed dual positive expression of CK7 and HOXB4 in the same cases of ovarian cancer and benign, so there were 25 (89%) cases showed positive expression in both CK7 and HOXB4, and the rest 3 (10.7%) cases were showed negative expression, while in benign there were 11 (44%) cases showed positive expression in both CK7 and HOXB4 and the rest 14 (56%) cases were showed negative expression in CK7 and HOXB4. There were highly significant ($p \leq 0.01$) differences between patients of ovarian cancer and benign in relation to expression of dual CK7 and HOXB4 table (4). The result showed that ovarian cancer had dual expression for CK7 and HOXB4 more than in benign patients, with highly significant difference $p < 0.01$. Coordinate expression for CK7 and HOXB4 are may be useful as a good tool for distinguishing ovarian cancer than other ovarian diseases such as benign hyperplasia. Helen and Mark (2002) showed that primary ovarian tumors have more dual CK7+/CK20+ expression than non-ovarian tumors [23]. On the other hand, HOXA4/HOXB3 gene expression used for prognostic risk stratification high-grade serous ovarian carcinoma patients [24].

Conclusion

Our study concluded there was no well correlation established between HOXB4 and CK7 protein in correlation with histopathological variables in ovarian cancer. Also development and progression of the ovarian carcinoma does not depend on HOXB4 and CK7 expression in correlation with histopathological variables (stage, grade, and type).

However a good correlation was found between above proteins in ovarian cancer, this role may be due to impact of CK7 and HOXB4 on the apoptosis of ovarian cells.

References

- [1] Fitzmaurice, C.; Dicker, D.; Pain, A.; Hamavid, H.; Moradi-Lakeh, M.; MacIntyre, M. F.; Wolfe, C., et al., (2015). The Global Burden of Cancer 2013. *JAMA Oncology*, 1 (4), 505.
- [2] Siegel, R. L.; Miller, K. D., and Jemal, A. (2016). Cancer statistics, 2016. *CA: A Cancer Journal for Clinicians*, 66 (1), 7–30
- [3] Wright, J.D.; Chen, L.; Tergas, A.I.; Patankar, S.; Burke, W.M.; Hou, J.Y.; Neugut, A.I.; Ananth, C.V. and Hershman DL. (2015) Trends in relative survival for ovarian cancer from 1975 to 2011. *Obstet. Gynecol.* 125, 1345–1352
- [4] Mavaddat, N., Peock, S., Frost, D., Ellis, S., Platte, R., Fineberg, E. et al., (2013). Cancer Risks for BRCA1 and BRCA2 Mutation Carriers: Results from Prospective Analysis of EMBRACE. *JNCI: Journal of the National Cancer Institute*, 105 (11), 812–822.
- [5] Ryerson, A.B.; Ehemann, C., Burton, J., et al. (2007). Symptoms, diagnoses, and time to key diagnostic procedures among older U.S. women with ovarian cancer. *Obstet Gynecol*; 109:1053–1061.
- [6] Sankaranarayanan, R., and Ferlay, J. (2006). Worldwide burden of gynaecological cancer: The size of the problem. *Best Practice & Research Clinical Obstetrics & Gynaecology*, 20 (2), 207–225.
- [7] Mackinder, MA.; Evans, CA.; Chowdry, J., Staton, CA. and Corfe BM. (2012). Alteration in composition of keratin intermediate filaments in a model of breast cancer progression and the potential to reverse hallmarks of metastasis. *Cancer Biomark*; 12: 49–64.
- [8] Kanaji, N.; Bando, S.; Fujita, J.; Ishii, T.; Ishida, T. and Kubo, A. (2007). Compensation of type I and type II cytokeratin pools in lung cancer. *Lung Cancer*, 55 (3), 295–302.
- [9] Kriplani, D. and Patel, M.M. (2013). Immunohistochemistry: A diagnostic aid in differentiating primary epithelial ovarian tumors and tumors metastatic to the ovary. *South Asian J Cancer*. 2 (4): 254–258.

- [10] **Alkusayer, G. M.; Peng, B.; Klausen, C.; Lisonkova, S.; Kinloch, M.; Yong, P. and Bedaiwy, M. A. (2015).** Expression of HOXB4 -in endometrial tissues from women with or without endometriosis. *Fertility and Sterility*, 104 (3), 157–158.
- [11] **Jackson, M.; Axton, RA.; Taylor, AH.; Wilson, JA.; Gordon-Keylock, SA.; Kokkaliaris, KD.; Brickman, JM.; Schulz, H.; Hummel, O. and Hubner, N.; Forrester, L. M. (2012).**HOXB4 can enhance the differentiation of embryonic stem cells by modulating the hematopoietic niche. *Stem cells*, 30 (2):150-16.
- [12] **Yamaguchi, K.; Mandai, M.; Toyokuni, S.; Hamanishi, J.; Higuchi, T.; Takakura, K. and Fujii, S. (2008).** Contents of endometriotic cysts, especially the high concentration of free iron, are a possible cause of carcinogenesis in the cysts through the iron-induced persistent oxidative stress. *Clin. Cancer Res.* 4, 32–40
- [13] **Naora, H.; Montz, F. J.; Chai, C.-Y. and Roden, R. B. S. (2001).** Aberrant expression of homeobox gene HOXA7 is associated with mullerian-like differentiation of epithelial ovarian tumors and the generation of a specific autologous antibody response. *Proceedings of the National Academy of Sciences*, 98 (26), 15209–15214
- [14] **Zhang, X. (2014).**The expression and invasion-suppressive function of HOXB4 in epithelial ovarian cancer, University of British Columbia. (1-220)
- [15] **Shin, J. H.; Bae, J. H.; Lee, A.; Jung, C.-K.; Yim, H. W.; Park, J.-S., and Lee, K.-Y. (2010).** CK7, CK20, CDX2 and MUC2 Immunohistochemical Staining Used To Distinguish Metastatic Colorectal Carcinoma Involving Ovary from Primary Ovarian Mucinous Adenocarcinoma. *Japanese Journal of Clinical Oncology*, 40 (3), 208–213
- [16] **Tot T. (2002).**Cytokeratins 20 and 7 as biomarkers: usefulness in discriminating primary from metastatic adenocarcinoma. *Eur J Cancer.* 38 (6):758-63
- [17] **Miyamoto, M., Takano, M., Aoyama, T., Soyama, H., Yoshikawa, T., Tsuda, H., and Furuya, K. (2018).** Seromucinous component in endometrioid endometrial carcinoma as a histological predictor of prognosis. *Journal of Gynecologic Oncology*, 29 (2).
- [18] **Vang R, Gown AM, Barry TS, Wheeler DT and Ronnett BM. (2006).** Ovarian atypical proliferative (borderline) mucinous tumors: gastrointestinal and seromucinous (endocervical-like) types are immunophenotypically distinctive. *Int J Gynecol Pathol* 2006; 25:83-9.
- [19] **Chan, C. W. M.; Wong, N. A.; Liu, Y.; Bicknell, D.; Turley, H.; Hollins, L., and Bodmer, W. F. (2009).** Gastrointestinal differentiation marker Cytokeratin 20 is regulated by homeobox gene CDX1. *Proceedings of the National Academy of Sciences*, 106 (6), 1936–1941
- [20] **Yamashita, T., Tazawa, S., Yawei, Z., Katayama, H., Kato, Y., Nishiwaki, K., Yokohama, Y., and Ishikawa, M. (2006).**Suppression of invasive characteristics by antisense production of expressed HOX gen in ovarian cancer cells. *Inter.J.Oncol.*28 (4):931-938
- [21] **Kelly, Z.L. (2014).**PhD thesis, HOX gene expression in ovaria cancer. Faculty of health and medical science university of surrey.1- 281.
- [22] **Kelly, Z., Moller-Levet, C., McGrath, S., Butler-Manuel, S., Kavitha Madhuri, T., Kierzek, A. M.; Pandha, H.;Morgan, R. and Michael, A. (2016).** The prognostic significance of specific HOXgene expression patterns in ovarian cancer. *International Journal of Cancer*, 139 (7), 1608–1617.
- [23] **Helen P. Cathro, and Mark H. (2002).**Expression of Cytokeratins 7 and 20 in Ovarian Neoplasia.*Am J Clin Pathol*; 117:944-951
- [24] **Katherine Miller, Jai N Patel, Qing Zhang and Eric J Norris (2018).**HOXA4/HOXB3 gene expression signature as a biomarker of recurrence in patients with high-grade serous ovarian cancer following primary cytoreductive surgery and first-line adjuvant chemotherapy, (Abstract).*Gynecologic Oncology* 149 (1)