

Over Expression of Apoptotic p53 and Epidermal Growth Factor Receptor in endometrial Cancer and Benign

Zainab Abdulrazzaq Hameed¹, Kareem Hamed Ghali²

¹Wasit University, College of Medicine, Iraq

²Wasit University, College of Science, Department of Biology, Iraq

Abstract: Endometrial carcinoma (EC) is one of commonest ten cancers, and represents fourth most widespread malignancy in females. The study included thirty samples of endometrial cancer's patients and twenty four patient's samples of benign were taken randomly as well as, twenty normal endometrial tissues as control group for comparison. This study was carried out in Laboratories of the College of Science/ Department of Biology, Wasit University, during period between October 2015 and April 2016. The study of p53 and EGFR expression was done by immunohistochemistry technique. The results showed significant increasing in expression and intensity of p53 in endometrial cancer patients when compared with control group ($P < 0.05$). Furthermore, the results also, showed significant increasing in expression and intensity of p53 in endometrial cancer patients comparing with benign patients ($P < 0.05$). Moreover, the results showed no significant between benign patients and control group in the expression and intensity of p53 ($P > 0.05$). On the other hand, the results showed that the EGFR is highly significant increasing in cancer patients comparing with control group and benign ($P < 0.05$). While, no significant different between benign patients and control in the expression and intensity of EGFR ($P > 0.05$). In conclusion, the present study confirms that p53 and EGFR play necessary roles carcinogenesis and develop of endometrial cancer because its impact on the apoptosis of tumor cells.

Keywords: P53, EGFR, Immunohistochemistry, Endometrial cancer

1. Introduction

Endometrial carcinoma (EC) is one of the most common malignancy of the womanly genital tract, it mainly happen in postmenopausal women, generally, 2.64% of women will develop EC through their lifetime [1]. Endometrial carcinoma is the most fourth widespread malignancy in females[2]. Endometrial cancers have long been divided into type I estrogen-dependent which is the much more common endometriosis adenocarcinoma (80%–90%) and type II estrogen-independent, the less common clinically aggressive, comprises non-endometriosis subtypes such as serous, clear cell [3]. The first symptom in patients with EC is abnormal uterine bleeding as symptom common [4]. The prevalence of uterine fibroids differs among 5% and 65% based on age, ethnicity, geographical area and quality of imaging technique[5]. The mechanism for advance of uterine fibroids to cancer is poorly understood. Both genetic features such as mutations and environmental factors such as obesity have been implicated in the advance of fibroids[6]. In addition, estrogen and progesterone can be affected on the transformation proses[7]. P53 gene is often referred to as the “guardian of the genome”, it is possibly one of the most important tumor suppressor genes, ways that prevent proliferation and survival of potentially malignant cells [8]. Damage-prompted apoptosis is a key feature of tumor suppression, in which p53 plays a chief role. A numbers of clinic researches have shown p53 mutations are closely linked with the endometrial carcinogenesis, mutated p53 as a nonfunctional protein collects in the cells (especially in nucleus) work as a dominate negative inhibitor of wild-kind p53, leading to the job loss of G1 arrest, resulting in evading apoptosis of cancer cells[9]. EGFR has been identified as an important biological factor in numerous human epithelial cancers comprising head and neck squamous cell carcinoma

(HNSCC), non-small cell lung cancer (NSCLC), colorectal cancer (CRC), breast, pancreatic, endometrial and brain cancer[10]. EGFR overexpression did not affect disease progression in kind I endometrial cancer, although affects disease progression in kind II endometrial cancer [11]. Mutation of the EGFR gene is an important biomarker for estimation of the impact of gefitinib, a molecular-targeted drug. Personalized medicine based on individual changes between patients is attainable utilizing therapy strategy with anticancer drugs chosen based on prediction of effects and reverse reactions utilizing these biomarkers[12].

2. Materials and Methods

Patients and tissue samples

Thirty samples of endometrial cancer's patients and twenty four patient's samples of benign were taken randomly and twenty normal endometrial tissues as control group for comparison. All specimens of patients were collected from Al-Zahraa and AL-Karama Teaching Hospitals in Wasit Province, and form Private Laboratory (Albeetar) in Dhi Qar Province. Fixed paraffin embedded tissue blocks were cut (4-5µm) thickness for each tissue block.

Immunohistochemistry (IHC):

P53 and EGFR antibodies and ABC staining system which were used provided by Santa Cruze Biotech. Inc. Serial tissue sections were cut 4- 5µm thick and positioned on positive charged slides. The slides were baked in 60-65°C oven over night. The tissue sections were deparaffinized; then the slides were rehydrated by graded ethanol concentration (100%, 95%, and 70%) and xylene concentration (100%) and distal water. The slides were treated with citrate buffer for 10 minutes, and then washed twice in distal water for 2 minutes. After preparation of

tissue sections, slides were incubated in 3% hydrogen peroxide (H₂O₂) diluted in D.W. for 7 minutes. Each slide was washed in PBS twice for 5 minutes. Sections were incubated for one hour in 1.5% blocking serum diluted with PBS. This step may be omitted if non-specific staining is not a problem. Primary antibody (prepared by adding 1 µl of the primary to 50 µl of 1.5% blocking serum diluted in PBS) was applied for 30 minutes at room temperature or overnight at 4° C in humidity chamber. Slides were washed with three changes of PBS for 5 minutes each, and then slides were incubated for 30 minutes with biotinylated secondary antibody and washed with two times of PBS for 5 minutes. Sections were incubated for 30 minutes with AB enzyme reagent, after that washed with two times of PBS for 5 minutes each. Sections were incubated in 1-3 drops peroxidase substrate for 9 minutes. The sections may be checked for staining by rinsing with H₂O and viewing under a microscope (if necessary added additional peroxidase substrate), then sections were washed one time in distilled water for 5 minutes. Counter stain slides, Hematoxylin stain was added on slides for 43 seconds. Immediately, slides rinsed with running tap water for 2 minutes. Dehydrated sections as follows: 1x 95% ethanol for 20 seconds and free ethanol at 2 times for 20 seconds and xylene at 1 time for 10 seconds. Immediately 1-2 of DPX solution was added and cover with glass coverslip. Finally, slides were observed by light microscope.

Ethical consent

The study was submitted and approved by the College of Science, University of Wasit in collaboration with AL-Karama and AL-Zahraa Teaching Hospitals, Wasit – Iraq.

Statistical analysis

For all statistical analyses, the SPSS system for personal computer was used, and p values of 0.05 or less were regarded as statistically significant. Sensitivity and

specificity of the tests (with 95% exact confidence intervals) were determined in studied group. Comparison between groups was carried out using Chi-square test.

Scoring system

Based on the percentage of stained cells and the intensity of nuclear stain. The staining intensity was scored as follows: The percentage of positive staining (P) were scored as 0 (negative), 1 (1%-25%), 2 (26%-50%), and 3 (51%-100%), and the levels of intensity of staining (I) were determined as 0 for negative; 1 for weak staining; 2 for moderate staining; and 3 for strong staining.

3. Results and Discussion

3.1 Expression of p53

3.1.1 P53 expression and intensity in endometrial cancer and control group

Immunohistochemistry (IHC) analysis of P53 expression was reported positive in 14 (46.6%) of endometrial cancer patients out of 30 cases and the rest 16 (53.4%) cases were showed negative staining for p53, while in control group 1 (5%) out of 20 cases were showed positive staining for p53 (fig1). There was highly significant differences between patients of endometrial cancer and control group in relation to p53 expression ($P < 0.05$). Intensity assessment of p53 expression in endometrial cancer patients showed that 16 (53.3%) with score 0, 2 (14.2%) cases with score +1, 8 (57.1%) cases with score +2, 4 (28.5%) cases with score +3. While in control group, 19 (95.0%) cases with score 0, 0 (0%) cases with score +1, in 1 (0.5%) cases with score +2, 0 (0%) cases with score +3. There were significant differences between patients of endometrial cancer and control group in relation to intensity of p53 expression ($P < 0.05$) (Table 1).

Table 1: P53 expression and intensity in endometrial cancer and control group

Case	Expression - +		Pvalue	0 No%	Intensity 1 23			P value	Total
	No	%			No	%	No		
Endometrial cancer patients	14(46.6%)	16(53.3%)	P<0.05	16(53.3%)	2(14.2%)	8(57.1%)	4(28.5%)	P<0.05	30(100.0%)
Control group	1(5%)	19(95%)		19(95.0%)	0(0%)	1(0.5%)	0(0%)		20(100.0%)
Total	15(30.0%)	35(70.0%)	50(100.0%)	35(70.0%)	2(4.0%)	9(18.0%)	4(8.0%)		50(100.0%)

($P < 0.001$, highly significant) (significant, $P < 0.05$)

Our results showed that expression of p53 in endometrium patients was strong and higher than control group. Results of [13] found that p53 expresses in 17 (48%) out of 35 endometrial patients. Moreover, [14] reported that p53 expression in 32.5% of patients while normal endometrium didn't appear showed p53 immunostaining. Also, [15] showed that no positive p53 expression in normal endometrium and simple endometrial hyperplasia but all cases of endometrial adenocarcinoma appeared p53 positive. However, [16] reported that p53 expression was detected in 15 (17.2%) cases out of 87 cases in endometrium carcinomas. but p53 expression was not detected in normal and hyperplastic endometrium, because in normal cells, p53 is quickly degraded and therefore cannot be distinguished by

immunostaining, p53 mutations create a non-functional protein that resists degradation and can be seen by immunostaining [17].

3.1.2. P53 expression and intensity in endometrial cancer and benign patients

Expression of p53 was reported positive in 14 (46.6%) of endometrial cancer patients out of 30 cases and the rest 16 (53.3%) cases were showed negative staining for p53, while in benign patients 1 (4.1%) out of 24 cases were showed positive staining for p53 and the rest 23 (95.8%) cases were showed negative staining. Intensity assessment of p53 expression in endometrial cancer patients showed that 16 (53.3%) cases with score 0, 2 (6.7%) cases with score +1, 8

(26.7% cases with score +2, 4 (13.3%) cases were score +3. While in benign patients, 23 (95.8%) cases with score 0, 0 (0%) cases with score +1, +2, 1 (4.2%) cases with

score +3. There were highly significant difference between endometrial cancer patients and benign group in relation to p53 expression ($p < 0.05$) (Table 2).

Table 2: P53 expression and intensity in endometrial cancer and benign patients

Case	Expression - +		Pvalue	0 No%	Intensity 1 2 3			P value	Total
	No %	No %			No %	No %	No %		
Endometrial cancer patients	14(46.6%)	16(53.3%)	$P < 0.05$	16(53.3%)	2(6.7%)	8(26.7%)	4(13.3%)	$P < 0.05$	30(100.0%)
Control group	1(4.1%)	23(95.8%)		23(95.8%)	0(0.0%)	0(0.0%)	1(4.2%)		24(100.0%)
Total	15(27.8%)	39(72.2%)		39(72.2%)	2(3.7%)	8(14.8%)	5(9.3%)		54(100.0%)

($P < 0.0001$, highly significant) ($P < 0.0001$, highly significant)

Our results showed significant increasing in expression and intensity of p53 in patients when compared with benign patients ($P < 0.001$). Results of [18] showed that p53 expression in 18 (39.1%) of 46 endometrial serous carcinoma (ESC), 6 (37.5%) of 16 endometrial intraepithelial carcinoma (EIC), 2 (3.3%) of 60 endometrial endometrioid carcinoma (EEC), and 1 (1.7%) of 60 benign. Moreover, [19] found p53 expression positive in 12 (50%) cases out of 24 of leiomyosarcoma (LMS) while negative expression in Leiomyoma (LM) for p53. Also, [20] showed that no expression of p53 in Leiomyoma and found in 7/17 cases of leiomyosarcoma with significant difference ($P = 0.002$). However, [21] showed that p53 expression was

stronger in papillary serous adenocarcinomas than in endometriosis adenocarcinomas and negative in benign endometrium. Overexpression for p53 in endometrial cancer patients may be responsible for the high proliferative activity of postmenopausal endometrial glandular cells associated with conditions of low apoptotic cell death [22].

3.1.3. P53 expression and intensity in benign patients and control group

The study demonstrated that no significant difference between control group and benign in relation to p53 expression and intensity ($P > 0.05$) (Table 3).

Table 3: P53 expression and intensity in benign patients and control group

Case	Expression - +		Pvalue	0 No%	Intensity 1 2 3			P value	Total
	No %	No %			No %	No %	No %		
Endometrial cancer patients	1(4.1%)	23(95.8%)	$P > 0.05$	23(95.8%)	0(0.0%)	0(0.0%)	1(4.2%)	$P > 0.05$	24(100.0%)
Control group	1(5.0%)	19(95.0%)		19(95.0%)	0(0.0%)	1(5.0%)	0(0.0%)		20(100.0%)
Total	2(4.5%)	42(95.5%)		42(95.5%)	0(0.0%)	1(2.3%)	1(2.3%)		44(100.0%)

($P > 0.05$, non-significant) ($P > 0.05$, non-significant)

our results showed that no significant between benign patients and control group in the expression and intensity of p53 ($P > 0.05$). Results of [23] found that p53 expression in endometrial polyps more frequency during the proliferative than during the luteal phase of the menstrual cycle and like results were observed in the normal endometrium because endometrial polyps suffer cyclic changes in the expression of their proteins associated to proliferation and apoptosis through the menstrual cycle, alike to those of the cycling endometrium [23]. Also current results agree with findings of Ahmed and Isaac. [14]; [15] and [16] who reported p53 expression was not detected in normal endometrial. Moreover, [21] found p53 expression negative in benign endometrium (Fig. 1).

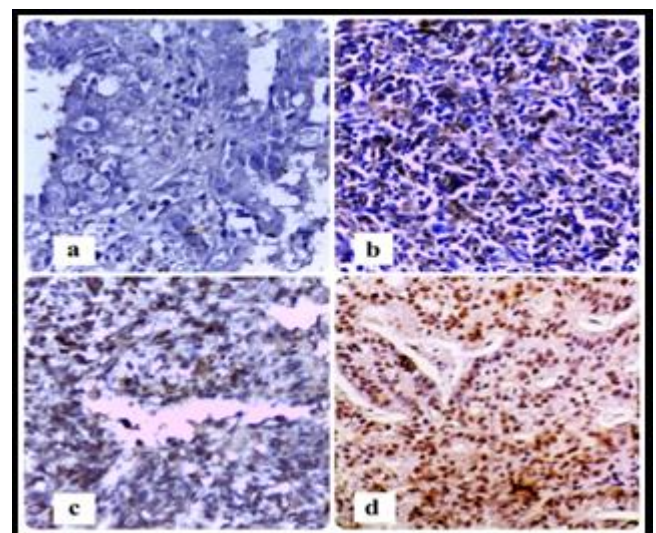


Figure 1: P53 IHC staining in endometrial patients. a. negative, b. score +1, c. score +2, d. score +3 (X40)

3.2 Expression of EGFR

3.2.1. EGFR expression and intensity endometrial cancer and control group

Immunohistochemistry (IHC) analysis of EGFR expression was reported, 20 (66.7%) cases of endometrial cancer patients out of 30 cases were showed positive staining while the rest 10 (33.3%) cases were showed negative, while in control group 3 (15.0%) out of 20 cases were showed positive staining and the rest 17 (85.0%) cases were showed negative staining. There was highly significant differences

between endometrial cancer patients and control group in relation to in relation to EGFR expression ($P < 0.05$). Intensity assessment of EGFR in endometrial cancer patients showed that 10 (33.3%) with score 0, 4 (13.3%) cases with score +1, 7 (23.3%) cases with score +2, , 9 (30.0%) cases were score +3. While in control group, 17 (85.0%) cases with score 0, 0 (0%) cases with score +1, 2 (10.0%) cases with score+2, 1 (5.0%) cases with score+3. There was no significant between endometrial cancer and control in the intensity of EGFR expression ($P > 0.05$) (Table 4).

Table 4: EGFR expression and intensity endometrial cancer and control group

Case	Expression - + No % No%		Pvalue	0 No%	Intensity 1 2 No% No% No%			P value	Total
Endometrial cancer patients	20(66.7%)	10(33.3%)	$P < 0.05$	10(33.3%)	4(13.3%)	7(23.3%)	9(30.0%)	$P > 0.05$	30(100.0%)
Control group	3(15.0%)	17(85.0%)		17(85.0%)	0(0.0%)	2(10.0%)	1(5.0%)		20(100.0%)
Total	23(46.0%)	27(54.0%)	50(100.0%)	27(54.0%)	4(8.0%)	9(18.0%)	10(20.0%)		50(100.0%)

($P < 0.0001$, highly significant) (non-significant $P > 0.05$)

Our study demonstrated that highly significant between endometrial cancer and control in the expression of EGFR ($P < 0.0001$). Results of [24] showed The positive EGFR expression in the endometrial cancer patients was higher than that in the normal endometrial tissues 41 (73. 2%) cases out of 56 cases vs 9 (30. 0%) cases out of 30 cases. Also [25] reported that EGFR is overexpressed in endometrial cancer compared with normal cycling endometrium. Moreover, [26] reported that EGFR is expressed in normal endometrial membrane and its overexpression is associated with the stage of endometrial cancer and a poor prognosis. Expression for EGFR in endometrial cancer because EGFR is the important member of ErbB/HER receptor tyrosine kinase family, which has been reported to involved in the development of human cancer [27]. The upregulated EGFR has been found in some human cancers, including endometrial cancer. This increased EGFR can promote the proliferation and metastasis of tumors by activating the downstream phosphatidylinositol 3-kinase (PI3K)/AKT

signal transduction [28]. PI3K/AKT signal transfer is correlated with the growth of human cancers by suppressing the apoptosis of tumor cells [29].

3.2.2. EGFR expression and intensity in endometrial cancer and benign patients.

The result showed 1 (4.2%) out of 24 benign cases was positive staining for EGFR and the rest 23 (95.8%) cases were showed negative staining. There was highly significant difference between endometrial cancer patients and benign group in relation to EGFR expression ($p < 0.05$). Intensity assessment of EGFR expression in benign patients, 23 (95.8%) cases with score 0, 0 (0%) case with score +1 and +3, 1 (4.2%) case with score +2. There was no significant difference between patients of endometria cancer and benign in relation to intensity of EGFR expression ($P > 0.05$) (Table 5).

Table 5: EGFR expression and intensity in endometrial cancer and benign patients

Case	Expression - + No % No%		Pvalue	0 No%	Intensity 1 2 No% No% No%			P value	Total
Endometrial cancer patients	20(66.7%)	10(33.3%)	$P < 0.05$	10(33.3%)	4(13.3%)	7(23.3%)	9(30.0%)	$P > 0.05$	30(100.0%)
Control group	1(4.2%)	23(95.8%)		23(95.8%)	0(0.0%)	1(4.2%)	0(0.0%)		24(100.0%)
Total	21(38.9%)	33(61.1%)	54(100.0%)	33(61.1%)	4(7.4%)	8(14.9%)	9(16.6%)		54(100.0%)

($P < 0.0001$, highly significant) ($P > 0.05$, non-significant)

Our results showed highly significant between endometrial cancer and benign in the expression of EGFR ($P < 0.0001$). Results of [30] found EGFR expression in 43-67% of endometrial cancer. Moreover, [31] demonstrated that EGFR overexpression has been pretended in both Type 1 and Type 2 in endometrial cancer. Also [32] reported that epidermal growth factor receptor (EGFR) overexpression has been detected in endometrial cancer. In addition, [33] showed

EGFR expression did not differ between uterine leiomyosarcoma and benign leiomyoma also they showed EGFR was not commonly expressed in leiomyosarcoma, this may be due to the cases of uterine leiomyosarcoma arising in leiomyoma [34].

3.2.3 EGFR expression and intensity in benign patients and control group

The study demonstrated that no significant differences between benign and control group in relation with EGFR expression and intensity as shown (Table 6). Group

Table 6: EGFR expression and intensity in benign patients and control

Case	Expression - +		Pvalue	0 No%	Intensity 1 2 3			P value	Total
	No	%			No	%	No		
Endometrial cancer patients	1	4.2%	P>0.05	23	95.8%	0	0%	P>0.05	24
Control group	3	15.0%		17	85.0%	0	0%		20
Total	4	9.1%		40	90.0%	0	0%		44

(P>0.05, non-significant)

(P>0.05, non-significant)

our results showed that no significant between benign patients and control group in the expression and intensity of EGFR (P>0.05). Results of [24] explained that EGFR expression in the normal endometrial tissues 9 (30. 0%)cases out of 30 cases (Fig.2).

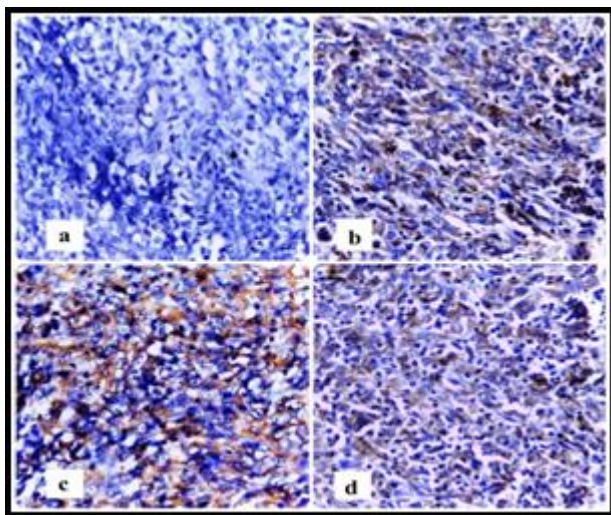


Figure 2: EGFR IHC staining in endometrial patients a. negative, b. score+1, c. score+2, d. score+3 (X40)

References

- [1] Adonakis, G.;Androutsopoulos, G.; Koumoundourou, D.; Liava, A. and Ravazoula, P. (2008).Expression of the epidermal growth factor system in endometrial cancer. *Eur J Gynaecol Oncol.* 29 (5):450-454.
- [2] Ahmed, N.Y.and Isaac, R.H. (2010).P53 expression in endometrial hyperplasia and endometrial carcinoma. *Zanco J. Med. Sci.*14 (2).
- [3] Ai, Z.; Wang, J. ; Wang, Y.; Lu, L.; Tong, J.; and Teng, Y. (2010).Overexpressed Epidermal Growth Factor Receptor (EGFR)-induced progestin insensitivity in human endometrial carcinoma cells by the EGFR/mitogen-activated protein kinase signaling pathway. *American Cancer Society.*116:3603–3613.
- [4] Altomare, D.A.; Wang, H.Q.; Skele, K.L.; De Rienzo, A.; Klein-Szanto, A.J.; Godwin, A.K. and Testa, J.R. (2004). AKT and mTOR phosphorylation is frequently detected in ovarian cancer and can be targeted to disrupt ovarian tumor cell growth. *Oncogene.* 23 (34): 5853-5857.
- [5] Anderson, S.E.; Nonaka, D. ; Chuai, S.; Olshen, A.B.; Chi, D.; Sabbatini, P. and Soslow, R.A. (2006).p53, epidermal growth factor, and platelet-derived growth factor in uterine leiomyosarcoma and leiomyomas.*Int J Gynecol Cancer.* 16 (2):849-853.
- [6] Androutsopoulos, G. ; Adonakis, G.; Liava, A.; Ravazoula, P. and Decavalas, G. (2013).Expression and potential role of ErbB receptors in type II endometrial cancer. *Eur J Obstet Gynecol Reprod Biol.*168:204-08.
- [7] Androutsopoulos, G. ; Michail, G.; Adonakis, G. and Decavalas, G. (2014). Molecular biology, expression and clinical significance of ErbB receptors in endometrial cancer. *Hel J Obst Gynecol.*13 (3):77-83.
- [8] Azimpouran, M.; Vazifekhah, S.; Moslemi, F.; Piri, R. and Behzad, M.N. (2016). Immunohistochemical profile of uterine leiomyomas; a comparison between different subtypes.*Niger Med J.* 57 (1): 54–58.
- [9] Baird, D.D.; Hill, M. C. ;Schechtman, J. M. and Hollis, B.W. (2013). Vitamin d and the risk of uterine fibroids. *Epidemiology.* 24 (3):447–453.
- [10]Brand, T.M. ; Iida, M. and Wheeler, D. L. (2011).Molecular mechanisms of resistance to the EGFR monoclonal antibody cetuximab.*CancerBiology & Therapy Journal.* 11 (9): 777–792.
- [11]Bulun, S.E. (2013).Uterine fibroids. *The New England journal of medicine.*369 (14):1344–1355.
- [12]Chiho, K.; Toru, H.; Midori, M.;Tomoko, K.;Thuy Thi, N.;Shohei, S. and Yoshihisa, F. (2015). Overexpression of p53 in the endometrial gland in postmenopausal women.*The Journal ofThe North American Menopause Society.*22 (1):104-107.
- [13]Garg, K.; Leitao, M.M.; Wynveen, C.A.; Sica, G.L.; Shia, J ; Shi, W and Soslow, R.A. (2010).p53 overexpression in morphologically ambiguous endometrial carcinomas correlates with adverse clinical outcomes.*Modern Pathology.*23 (1) 80–92.
- [14]Herbst, R.S. (2004). Review of epidermal growth factor receptor biology. *Int J Radiat Oncol Biol Phys.*59: 21-26.
- [15]Ilie, D.;Georgescu, C.V.;Simionescu, C.and Braila, A.D. (2011).Immunohistochemical aspects of endometrium hyperplasias in perimenopause. *Current Health Sciences Journal.*37 (2):85-91.
- [16]Ioachima, E.E., Goussiaa, A.C.; Kitsioub, E.G. ;Charalabopoulos, K.; Mermigab, E. and Stefanakib, S. (2002).Immunohistochemical expression of retinoblastoma gene product in normal, hyperplastic and

- malignant endometrium. Correlation with p53 protein expression, c-erbB-2, hormone receptors' status and proliferative activity. *Disease Markers*.18 : 143–152.
- [17] Janiec-Jankowska, A.; Konopka, B.; Goluda, C. and Najmoła, U. (2010).Tp53mutations in endometrial cancers: relation to PTEN gene defects. *International Journal of Gynecological Cancer*. 20 (2):196–202.
- [18] Jatoi, N. (2003). Leiomyosarcoma: raremalignant change in a leiomyoma. *J Coll Physicians Surg Pak*.13:106–107.
- [19] Konecny, G.; Santos, L.; Winterhoff, B. and et al. (2009). HER2 geneamplification andEGFR expression in a large cohort of surgically staged patients with nonendometrioid (type II) endometrial cancer. *Br J Cancer*.100:89-95.
- [20] Kounelis, S.; Kapranos, N.; Kouri, E. ; Coppola, D.;Papadaki, H. and Jones, M.W. (2000). Immunohistochemical profile of endometrial adenocarcinoma: a studyof 61 cases and review of the literature. *Mod Pathol J*.13 (4):379–38.
- [21] Lax, S.F. (2004). Molecular genetic pathways in various types of endometrial carcinoma: from a phenotypical to a molecular-based classification, *VirchowsArchiv*. 444 (3) : 213-223.
- [22] Magdnlana, B.; Andrzej, S.; Tomasz, R. (2007). Expression of erbB-1 and erbB-2 genes in normal and pathological human endometrium. *Oncol Rep*. 18:261-265.
- [23] Maia, H.J.; Maltez, A.; Studart, E.; Athayde, C. and Coutinho, E.M. (2004).Ki-67, Bcl-2 and p53 expression in endometrial polyps and in the normal endometrium during the menstrual cycle.*BJOG*. 111 (11):1242-1247.
- [24] Olayioye, M.A.; Neve, R.M.; Lane, H.A. and Hynes, N.E. (2000).The ErbB signaling network: receptor heterodimerization in development and cancer. *EMBO J*.19 (13): 3159-3167.
- [25] Petrovic, D.; Babic, D.; Forko, J.I. and Martinac, I. (2010).Expression of Ki-67, P53 and progesterone receptors in uterine smooth muscle tumors. *Diagnostic value.CollAntropol*. 34 (1):93-7.
- [26] Segars, J.H.; Parrott, E.C.; Nagel, J.D.; Guo, X.C.; Gao, X. Birnbaum, L.S.; Pinn, V. W. and Dixon, D. (2014).Proceedings from the Third National Institutes of Health International Congress on Advances in Uterine Leiomyoma Research: comprehensive review, conference summary and future recommendations. *Human reproduction update*. 0 (0) :1–25.
- [27] Setiawan, V.W.; Yang, H.P.; Pike, M.C.; McCann, S.E. ;Yu, H.; Xiang, Y.B.; Wolk, A.; Wentzensen, N.; Weiss, N.S.; Webb, P.M. and et al. (2013). Type I and IIendometrial cancers: have they different risk factors. *J Clin Oncol*. 31 (20):2607-2718.
- [28] Siegel, R.; Naishadham, D. and Jemal, A. (2013).Cancer statistics (2013) *CA Cancer J Clin*.63 (1):11-30.
- [29] Siegel, R. ;Naishadham, D. and Jemal, A. (2012). Cancer statistics, 2012. *CA Cancer J Clin*. 62 (1):10–29.
- [30] Sorosky, J.I. (2012).Endometrial cancer. *Obstetrics & Gynecology*.120 (2, Pa1):383-397.
- [31] Zagouri F.; Bozas G.; Kafantari E.; Tsiatas, M.; Nikitas, N.;Dimopoulos.M. A.; Papadimitriou, C.A. (2010). Endometrial cancer: what is new in adjuvant and molecularly targeted therapy? *Obstet Gynecol Int*. (2010):11.
- [32] Zhang, L. and Fu, F. (2013).EGFR protein expression and EGFR gene mutation in endometrial carcinoma.*Chinese Journal of Cancer Biotherapy*. 20 (1):99-104.
- [33] Zhang, X; Liang, S.X.; Jia, L.; Chen, N.; Fadare, O. ;Schwartz, P.E.; Kong, B. and ZhengW. (2009). Molecular identification of “Latent Precancers” for endometrial serous, carcinoma in benign-appearing endometrium. *Am J Pathol*. 174 (6):2000-2006.
- [34] Zheltukhin, A. O. and Chumakov P. M. (2010). Constitutive and induced functions of the p53 gene. *Biochemistry (Mosc)*. 75:1692-1721+64.